

ASSESSMENT OF INFRAZYGOMATIC BONE THICKNESS FOR SAFE PLACEMENT OF INFRAZYGOMATIC IMPLANT IN PAKISTANI POPULATION; A CBCT STUDY

Ujala Saif ¹, Ahsan Mehmood Shah ¹, Sundus Shabir ¹, Sana Sajjad ¹, Komal Majeed ¹, Rubina Noor ¹

ABSTRACT

Objective: To evaluate infrazygomatic bone thickness for safe placement of infrazygomatic implant using CBCT.

Methods: This retrospective cross-sectional study was conducted in Orthodontics department of Khyber College of Dentistry, Peshawar. Computed tomographic records of 116 patients were taken to assess bone thickness in the coronal view. Measurements were made along the distobuccal root of 1st molar at angles ranging from 55° to 75° to maxillary occlusal plane and a line tangent to distobuccal root of 1st molar. Data was represented as tables and figures. Independent samples t test was employed to see the relation of the insertion angles and mean height from occlusal plane with gender.

Results: Bone thickness at infrazygomatic crest region varied at different insertion angles. Bone thickness at insertion angles of 55° to 75° ranged from 3.07 ± 0.94mm to 4.91 ± 1.59mm to maxillary occlusal plane. This value increased with increasing insertion angles. The height from occlusal plane also varied with higher values at small insertion angle i.e., 18.5mm at 55° and smaller values at high insertion angle i.e., 16.02mm at 75°. There was a significant difference in insertion heights from occlusal plane at insertion angles of 60°-75° according to gender, with higher insertion position in males (p value <0.05).

Conclusions: For minimum bone support of 3mm at infrazygomatic bone crest & safe placement of screw without injuring distobuccal root, the miniscrew should be inserted at an angle of 55° to 70° at distances of 16mm to 18mm from maxillary occlusal plan.

Keywords: Cone Beam Computed Topography, Dental Implants, Oral surgical procedu

INTRODUCTION

The achievement of anchorage has been challenging for obtaining the desired tooth movement.¹⁻⁴ Many conventional approaches; such as head gear, lingual arches; are either bulky or un comfortable, affecting patient compliance.¹⁻³ Furthermore, the desired tooth movement via these appliances is not always guaranteed.⁵ These adverse effects have been overcome by the development of skeletal anchorage.^{6,7}

Among them, infrazygomatic crest (IZC) implant is gaining popularity as a means of achieving skeletal anchorage. Anatomically IZC is an extra alveolar site, with bicortical bone, which provides greater anchorage and support as compared to mono cortical plate.⁸⁻¹⁰ Many studies have found the IZC bone thickness to be more than 1.00mm hence provides greater stability¹¹⁻¹³ and has been successfully used for space closure, anterior retraction, posterior intrusion and full arch distalization.^{14,15}

1. Khyber College of Dentistry, Peshawar, Pakistan

Murugesan et al.¹ found infrazygomatic crest bone thickness of 4.5 mm to 9 mm for the Dravidian population, when measured at an angle of 40° to 75° to the maxillary first molar occlusal plane and 11 to 17 mm above the occlusal plane. Al Amri et al.¹⁶ found mean thickness of 4.9mm at 40° insertion angle and 3.90mm at 70° for Saudi population

Address for Correspondence:

Dr. Ahsan Mehmood Shah

Associate professor, Department of Orthodontics, Khyber College of Dentistry, Peshawar, Pakistan

ahsanmshah@gmail.com

+9231339117622

Great variations exist in IZC bone thickness in different populations.^{1,12,16} Keeping in mind the differences in bone thickness among different

population and chances of IZC mini screw to hit the vital structures lying in close proximity such as maxillary sinus, roots of maxillary molars, to IZC bone, it is important to assess the thickness of IZC for safe surgical placement of mini screws.

The appropriate thickness and angles for insertion of mini screws at infrazygomatic crest has not been documented for Pakistani population. The aim of this study is to locate the safe zone for placement of IZC implant insertion via CBCT in the Pakistani population.

MATERIAL AND METHODS:

This retrospective cross-sectional study was conducted in the Orthodontics and Dentofacial Orthopaedics Department of Khyber College of Dentistry, Peshawar from December 2020 to March 2021. Permission to conduct this study was granted by the ethical committee of Khyber College of Dentistry, Peshawar (letter no. 15 ADR/KCD). The sampling technique employed was nonprobability consecutive sampling. By using OpenEpi, the total sample size was calculated to be 116, by taking bone thickness

at 70° ($7.7^\circ \pm 1.9$) and 75° ($8.8^\circ \pm 2.3$)¹² while keeping 95% confidence interval and 80% power of test.

The sample consisted of 116 participants who came to the orthodontics department seeking orthodontic treatment, who already advised CBCT as an aid in their treatment were planning. The included participants were above 16 years which corresponded to CVM stage 5 and 6 as major skeletal growth is completed at this stage and bone quality also improves with age.¹⁷ The exclusion criteria were presence of bone lesions, craniofacial syndromes, facial asymmetry, impaction and history of previous surgeries in the upper molar region.

The infrazygomatic bone thickness and height from the maxillary occlusal plane was measured via CBCT. In the present study the measurements were made according to the method described previously in a study by Liou et al.¹² The distobuccal root of maxillary first molar was located first on sagittal view and it was oriented in all three planes (sagittal, axial, coronal) of CBCT images (figure 1).

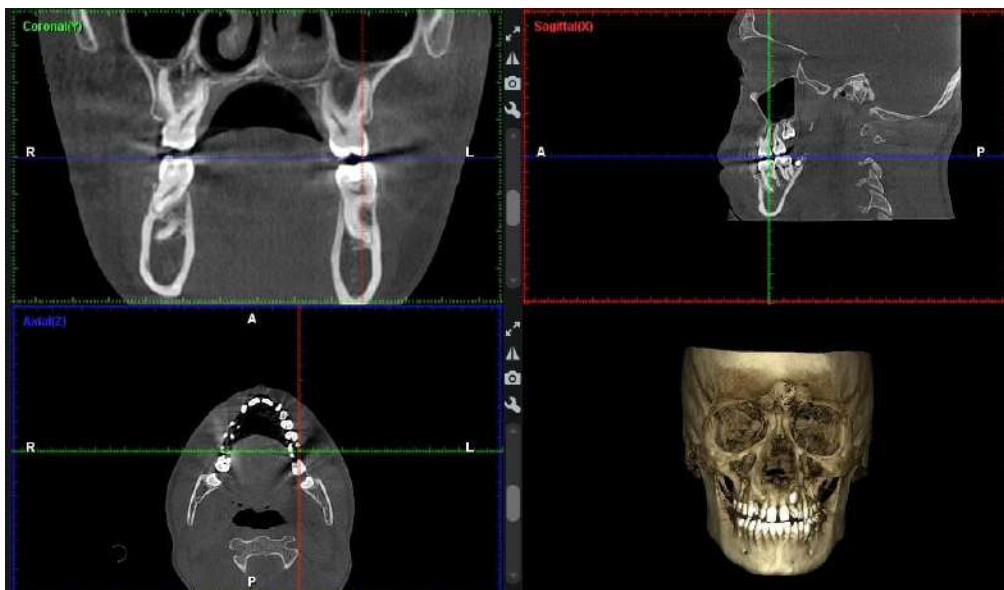


Figure 1. CBCT image being oriented in all three planes. Coronal, sagittal, axial view to locate accurately the distobuccal root of maxillary 1st molar

The measurements were then taken in coronal view. Two reference lines were taken on the coronal images, a horizontal line (blue) passing at cusp level of maxillary first permanent molar, representing maxillary occlusal plane, the second line passing tangent to the distobuccal root of maxillary first molar (red line). This tangent line was the limiting zone representing the root border, whereby crossing this would cause root injury (figure 2).

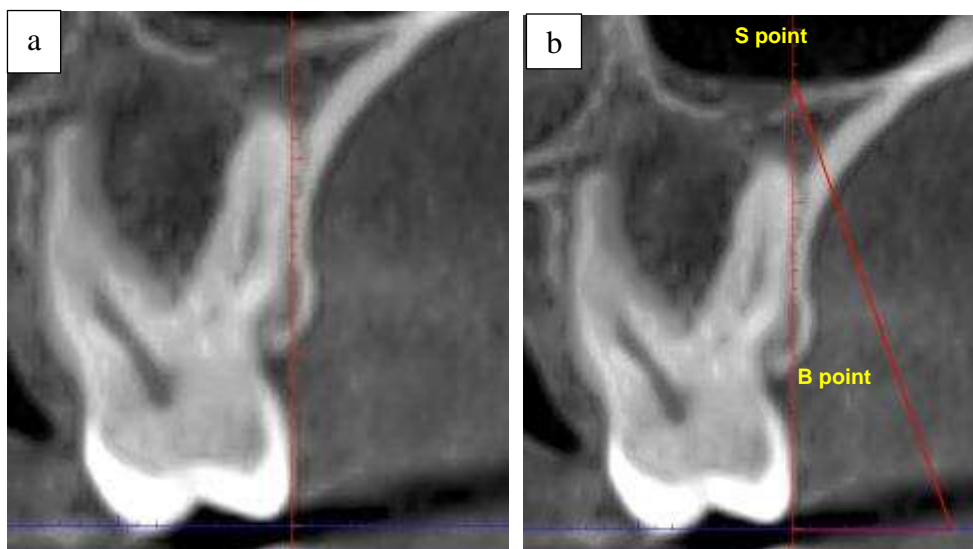


Figure 2. (a) vertical reference line (red line), horizontal (blue line) reference lines (b) reference point for measurements.

The point where the red line reaches the sinus floor is S point (sinus point). Five different angles to the maxillary occlusal plane were drawn ranging from 55° to 75° which intersected at S point. For each insertion angle, the line from the occlusal plane intersected at the buccal cortical plate, which was named B1, B2, B3, B4 and B5 corresponding to 55°, 60°, 65°, 70° and 75° respectively. The infrazygomatic bone thickness was measured from S point to the points B1, B2, B3, B4 and B5. The vertical distance for each insertion angle was measured from their respective B point to the maxillary occlusal plane. As no significant difference has been found between left and right side of bone thickness in multiple studies, the measurements were carried out on left side.^{1,7,18} Data collected was analysed by IBM SPSS 25.0. Frequency and percentages

were calculated for gender of participants. Means and standard deviations were calculated for age, bone thickness and height from maxillary occlusal plane. Independent t test was done for relation of bone thickness and height from occlusal plane with gender.

RESULTS

Out of the total 116 participants, 71 (39%) were males and 45 (61%) were females. The mean age of the participants was 23.03 ± 3.92 years.

The bone thickness at IZC varied at different insertion angles. The thickness of bone at the insertion angles of 55° to 75° ranged from 3.07 ± 0.94 mm to 4.91 ± 1.59 mm to maxillary occlusal plane. This value increased with increasing insertion angles. (Table 1)

Table 1: Mean Bone thickness at different insertion angles.

Ins. Angle (°)	Mean BT (mm)	SD
55	3.07	0.94
60	3.43	1.00
65	3.79	1.10
70	4.24	1.24
75	4.91	1.56

Ins. Angle: Insertion angle, BT: Bone thickness, SD= Standard Deviation

The height from occlusal plane also varied with different mini screw insertion angles with higher values at small insertion angle i.e., 18.5 mm at 55° and smaller values at high insertion angle i.e., 16.02 mm at 75°. (Table 2)

Table 2: Mean height from occlusal plan at different insertion angle

Ins. Angles (°)	Mean Height from OP (mm)	SD
55	18.40	2.99
60	17.86	3.05
65	17.37	3.13
70	16.79	3.29
75	16.02	3.59

Ins. Angle= Insertion angle, OP= Occlusal plane, SD= Standard Deviation

The results of the independent sample's t test showed no significant difference in bone thickness between males and females with a p value >0.05 (Table 3).

Table 3: Independent sample's t test for comparison of Mean bone thickness with gender.

Ins. Angles (°)	Mean BT (mm)		P value
	Males	Females	
55	3.10 ± 1.02	3.04 ± 0.79	0.74
60	3.47 ± 1.09	3.38 ± 0.85	0.61
65	3.80 ± 1.18	3.77 ± 0.97	0.88
70	4.28 ± 1.33	4.16 ± 1.09	0.62
75	4.95 ± 1.60	4.86 ± 1.51	0.58

Ins. Angle= insertion angle, BT= Bone Thickness.

However, there was a significant difference in insertion heights from occlusal plane at insertion angles of 60° 75° with higher insertion position in males than in females (p value <0.05). The height from occlusal plane at 55° insertion angle showed insignificant relationship with gender (p value >0.05). (Table 4)

Table 4: Independent sample's t test for comparison of mean height from occlusal plane with gender.

Ins. Angle (°)	Mean Height from OP (mm)		P value
	Males	Females	
55	19.05 ± 3.25	17.38 ± 2.19	0.75
60	18.51 ± 3.28	16.86 ± 2.34	0.003
65	18.04 ± 3.31	16.32 ± 2.52	0.004
70	17.43 ± 3.44	15.80 ± 2.81	0.009
75	16.70 ± 3.69	14.95 ± 3.18	0.01

Ins. Angle = Insertion angle, OP= Occlusal Plane.

DISCUSSION:

In the present study bone thickness of IZC was measured at the level of distobuccal root of maxillary first molar as the area lateral to maxillary 1st and 2nd molar is considered as an ideal site for insertion of IZC screw^{19,20} due to the fact that greater bone thickness for IZC implant insertion has been found in the multiple studies.^{1,2,7,12}

In our study, CBCT images were used to assess the bone thickness as it provides high resolution 3D images, with no magnification or superimposition errors and is a standard imaging technique when compared to 2D conventional imaging technique.^{10,21}

In the present study the results showed an average bone thickness of 3.07 ± 0.94mm to 4.91 ± 1.59 mm at 55° to 75° angle & at distance ranging from 18.40 ± 2.99 mm to 16.02 ± 3.59

mm with reference to maxillary occlusal plane. The bone thickness was found to increase as the insertion angle was increased at 5° increments from 55° to 75°. The result of this study shows that the distance from maxillary occlusal plane decreases as the angle of insertion increases. The same pattern was also noted by Liou et al.¹² and Murugesan et al.¹ Liou et al found bone thickness of 5.2 ± 1.1mm, at an angle of 40° and 8.8 ± 2.3mm at an angle of 75° to the maxillary occlusal plane, at a distance of 17.0 ± 3.7 mm & 12.8 ± 4.2 mm above maxillary occlusal plane. Murugesan et al noted the bone thickness of 4.5 mm to 9 mm in the infrazygomatic crest when measured at angle of 40° to 75° to the occlusal plane and 11mm to 17 mm above the occlusal plane.

However, the present study demonstrate that the bone thickness is small when compared to bone thickness found in other studies which

might be due to ethnic differences between the population under study and that studied previously. Hence the screw size recommended^{19,22,23} might not be suitable in our population as the chances of sinus perforation will increase as reported by Hans MG et al.⁷ who reported in his study that there is increase chance of sinus perforation when miniscrew of 6mm length or more is used. Motoyoshi et al.⁶ found the frequency of sinus perforation with IZC implants, to be 10% . Chang et al.²⁴ also reported it in 48% of the cases where conventional size of IZC implants were used. However Jia X et al.¹⁴ reported that even with 78% of IZC implants that penetrated into maxillary sinus, success rate was 96.7%, which was attributed to limited penetration of sinus <1mm & contact of the screw with bicortical plate of IZC .

In the present study the IZC thickness were compared between males and females; the results of which showed no significant difference in bone thickness between the two genders. The same results were found in study conducted by Rossi M et al.²⁵ in 2017 who found no significant difference in bone thickness and density between males and females.

The limitations of the study are that it is a retrospective cross-sectional study, and the results cannot be generalized. The soft tissue thickness at different insertion angles, the sagittal and vertical skeletal growth pattern were not taken into consideration, which might have influence on screw size selection.

Conclusion:

1. For minimum bone support of 3mm the miniscrew should be inserted at an angle of 55° to 70° at distances of 16mm to 18mm from maxillary occlusal plane.
2. The IZC bone thickness found in Pakistani population is thin when compared to other populations
3. There are chances of sinus perforation with conventional screw length being recommended
4. Soft tissue must be taken into consideration for selecting appropriate screw size

DECLARATIONS

Authors contributions:

Conception/Design: Ujala Saif, Ahsan Mehmood Shah.

Data Collection/Analysis/Interpretation: Ujala Saif, Ahsan Mehmood Shah, Sundus

Shabir, Sana Sajjad, Komal Majeed, Rubina Noor.

Manuscript Writing/Approval: Ujala Saif, Ahsan Mehmood Shah, Sundus Shabir, Sana Sajjad, Komal Majeed, Rubina Noor.

Conflicts of Interests:

None

Funding:

None

Acknowledgements:

None.

REFERENCES

1. Murugesan A, Sivakumar A. Comparison of bone thickness in infrazygomatic crest area at various miniscrew insertion angles in Dravidian population – A cone beam computed tomography study. *Int Orthod*. 2020;18(1):105–14.
2. Santos AR, Castellucci M, Crusoé-Rebello IM, Sobral MC. Assessing bone thickness in the infrazygomatic crest area aiming the orthodontic miniplates positioning: A tomographic study. *Dental Press J Orthod*. 2017;22(4):70–6.
3. Liu H, Wu X, Yang L, Ding Y. Safe zones for miniscrews in maxillary dentition distalization assessed with cone-beam computed tomography. *Am J Orthod Dentofac Orthop*. 2017;151(3):500–6.
4. Poon Y, Chang H, Tseng Y, Chou S. ScienceDirect Palatal bone thickness and associated factors in adult miniscrew placements: A cone-beam computed tomography study. *Kaohsiung J Med Sci*. 2015;31(5):265–70.
5. Wu X, Liu H, Luo C, Li Y, Ding Y. Three-dimensional evaluation on the effect of maxillary dentition distalization with miniscrews implanted in the infrazygomatic crest. *Implant Dent*. 2018;27(1):22–7.
6. Motoyoshi M, Sanuki-Suzuki R, Uchida Y, Saiki A, Shimizu N. Maxillary sinus perforation by orthodontic anchor screws. *J Oral Sci*. 2015;57(2):95–100.
7. Baumgaertel S, Hans MG. Assessment of infrazygomatic bone depth for mini-screw insertion. *Clin Oral Implants Res*. 2009;20(6):638–42.
8. Tavares A, Montanha-Andrade K, Cury PR, Crusoé-Rebello I, Neves FS. Tomographic assessment of infrazygomatic crest bone depth for extra-alveolar miniscrew insertion in subjects with different vertical and sagittal

- skeletal patterns. *Orthod Craniofacial Res.* 2022;25(1):49–54.
9. Khan J, Goyal M, Kumar M, Kushwah A, Kaur A, Sharma M. Comparative evaluation of displacement and stress distribution pattern during maxillary arch distalization with Infra Zygomatic Screw- A three dimensional finite element study. *Int Orthod.* 2021;19(2):291–300.
 10. Karim N. Anatomical assessment of cortical bone in mandibular buccal shelf in adults for orthodontic bone screw in a sample of population in Erbil city (a CBCT study). *Erbil Dent J.* 2022;5(1):19–30.
 11. Paul P, Mathur AK, Chitra P. Cone beam computed tomographic comparison of infrazygomatic crest bone thickness in patients with different facial types. *Orthod Waves.* 2020;79(2–3):99–104.
 12. Liou EJW, Chen PH, Wang YC, Lin JCY. A computed tomographic image study on the thickness of the infrazygomatic crest of the maxilla and its clinical implications for miniscrew insertion. *Am J Orthod Dentofac Orthop.* 2007;131(3):352–6.
 13. Du B, Zhu J, Li L, Fan T, Tan J, Li J. Bone depth and thickness of different infrazygomatic crest miniscrew insertion paths between the first and second maxillary molars for distal tooth movement: A 3-dimensional assessment. *Am J Orthod Dentofac Orthop.* 2021;160(1):113–23.
 14. Jia X, Chen X, Huang X. Influence of orthodontic mini-implant penetration of the maxillary sinus in the infrazygomatic crest region. *Am J Orthod Dentofac Orthop.* 2018;153(5):656–61.
 15. Bayome M, Park JH, Bay C, Kook YA. Distalization of maxillary molars using temporary skeletal anchorage devices: A systematic review and meta-analysis. *Orthod Craniofacial Res.* 2021;24(S1):103–12.
 16. Al Amri MS, Sabban HM, Alsaggaf DH, Alsulaimani FF, Al-Turki GA, Al-Zahrani MS, et al. Anatomical consideration for optimal position of orthodontic miniscrews in the maxilla: A CBCT appraisal. *Ann Saudi Med.* 2020;40(4):330–7.
 17. Krishnakumaran M, Krishnan B, Raman R, Rangarajan S, Preethi G, Chinnasamy A. Correlation of Infrazygomatic Bone Thickness With Cervical Vertebrae Maturation Stages. *J Indian Orthod Soc.* 2022;56(2):132–9.
 18. Murugesan A, Jain RK. A 3D comparison of dimension of infrazygomatic crest region in different vertical skeletal patterns: A retrospective study. *Int Orthod.* 2020;18(4):770–5.
 19. Chang CH, Lin JS, Yeh HY, Roberts WE. Insights to extraradicular bone screw applications for challenging malocclusions. *Tempor Anchorage Devices Clin Orthod.* 2020;433–44.
 20. Chang CCH, Lin JSY, Yeh HY. Extra-Alveolar Bone Screws for Conservative Correction of Severe Malocclusion Without Extractions or Orthognathic Surgery. *Curr Osteoporos Rep.* 2018;16(4):387–94.
 21. Kapila SD, Nervina JM. CBCT in orthodontics: Assessment of treatment outcomes and indications for its use. *Dentomaxillofacial Radiol.* 2015;44(1).
 22. Uribe F, Mehr R, Mathur A, Janakiraman N, Allareddy V. Failure rates of mini-implants placed in the infrazygomatic region. *Prog Orthod.* 2015;16(1).
 23. Kathia DR, Singla DA, Puri DA, Gogoi DJJ, Tulsyan DA. Skeletal anchorage system in orthodontics: A literature review. *Int J Appl Dent Sci.* 2022;8(2):377–80.
 24. Chang CH, Lin JH, Roberts WE. Success of infrazygomatic crest bone screws: patient age, insertion angle, sinus penetration, and terminal insertion torque. *Am J Orthod Dentofac Orthop.* 2022 Jun 1;161(6):783–90.
 25. Rossi M, Bruno G, De Stefani A, Perri A, Gracco A. Quantitative CBCT evaluation of maxillary and mandibular cortical bone thickness and density variability for orthodontic miniplate placement. *Int Orthod.* 2017;15(4):610–24.