

# Reconstruction of Posterolateral heel defect with lateral calcaneal artery flap: An experience at Burns at plastic surgery center Peshawar

Muhammad Hamayun Shinwari<sup>1</sup>, Irfan ullah<sup>1</sup>, Muhammad Bilal<sup>1</sup>, Syed Asif shah<sup>1</sup>

## Abstract

**Objective:** To evaluate the functional outcome of lateral calcaneal artery flap for coverage of the posterolateral heel defect

**Methods:** We share our experience of lateral calcaneal artery flap for the coverage of soft tissue defects. This study was conducted at Burns and Plastic Surgery Center, Hayatabad, Peshawar from July 2019 to June 2020. This axial flap was designed as a transposition flap based on lateral calcaneal artery and donor site is covered with partial thickness skin graft

**Results:** Ten patients with soft tissue defects, with or without visible calcaneus or Achilles tendon in posterior heel of various etiologies were treated with lateral calcaneal artery flap. In nine patients flap survived completely however one flap has epidermal loss which healed completely with moist dressing subsequently. Two patients had partial loss of STSG at donor site which was managed conservatively with local application of topical steroidal ointment. Sensory loss was observed at lateral aspect of foot in all patients with minimal patient concerns. All patients used regular normal shoes after 6 weeks after surgery with no notable adversity

**Conclusions:** Based on perioperative morbidity, coverage adequacy, aesthetical and functional outcome, we can safely state that the lateral calcaneal artery flap is a safe and reliable flap for the coverage of posterior heel and lateral calcaneal soft tissue defects.

**Keywords:** Posterolateral heel defects, Split-thickness skin graft, Lateral calcaneal artery flap

## Introduction

Reconstructive surgeons face numerous issues while treating defects of soft tissues around posterior heel (both weight bearing and non-weight bearing but with exposed tendoachilles tendon) due to their tendinous or osseous bed, poor vascularization, scarcity of pliable surrounding/lateral soft tissues, high-functional demands and rigorous mobility.

Multiple reconstructive strategies have been described ranging from application of skin grafts, local rearrangement of tissues, regional flaps, and free flaps transfers. All these options have their own indications, merits, and demerits.

1. Department of Burns and Plastic Surgery Center, Hayatabad, Peshawar

---

## Address for correspondence

**Dr. Irfan Ullah**

Assistant Professor, Burns and Plastic Surgery Center, Hayatabad Peshawar.

[drirfann@gmail.com](mailto:drirfann@gmail.com)

0092314-9076335

Reconstructive options are based on multiple factors like mode of trauma, size of the soft tissue defect, wound bed conditions and patients' general condition.

Skin graft is a simple option, but it is usually indicated for superficial clean dermal wounds. However, it cannot be applied to defects with osseous or tendinous bed also it does not withstand shear forces of shoe wear in long term.

Local flap for such defect includes medial planter artery flap, lateral calcaneal artery flap, and perforator-based flaps. The Medial planter artery flap is a versatile flap which is usually reserved for anterior weight-bearing heel to replace like with like tissue. Lateral calcaneal artery flap has been occasionally described for posterior non weight bearing defects in literature. Perforator based flaps has also been described for such defects.

Regional options like reverse sural artery flaps, Cross legs flap has also been described. They have major donor site morbidities as well as higher rate of flap failures due to venous or arterial insufficiencies as well wound dehiscence.

Free flaps have been extensively advocated in contemporary practices for traumatic tissue loss around ankle and lower 1/3 of leg. These can be applied for almost all types and size of soft tissue loss. It gives freedom of transfer of soft tissue components like fasciocutaneous, musculocutaneous and sensate tissue. The drawback of free flaps is that it is technically demanding flaps and is not always reliable in high velocity trauma patients.

Grabb and Argenta first described the lateral calcaneal artery flap for soft tissue defects of posterior heel. Numerous flap modification has been made there after.

We catalogue medical consequence of implementation of the pedicled lateral calcaneal artery flap to cover the posterior heel without or with visible calcaneus or Achilles tendon or in this paper.

### **Materials and Method:**

This descriptive study was performed at Burns and Plastic Surgery Center, Hayatabad, Peshawar from July 2019 to June 2020. Thirteen (n=13) patients with heel injuries have been enrolled in the study after obtaining an informed consent. Both male and female with age range from 20 to 60 years with soft tissue loss of posterior heel with exposed tendon and bone only were included. Patients with wounds involving anterior heel and lower third of legs were excluded. Comorbidities like diabetes were not considered in this study. Age, sex, mode of trauma, size of the wound, flaps dimensions, donor and recipient morbidity like flap viability, graft take, sensory loss were recorded in a proforma. Patients are followed weekly for first month and followed for 6 months thereafter. Shoe wear was started at 6 weeks postoperatively.

### **Technical Aspect of Flap:**

Surgeries were performed under general anesthesia in all patients. Handheld doppler were used to mark the artery with the patient in supine position on operating table. On the skin the site and path of the calcaneal artery was marked with skin marker. The width and length of the anticipated flaps were designed in a reverse template fashion, according to the defect size (Fig. 1. B). Flap should cover the defect size and arcs onward to the 5<sup>th</sup> metatarsal base, that is why it was designed either like long flap or like short vertical flap.

Tourniquet was applied at mid-thigh level. Incisions were started all around the marked skin area. The dissection was started from distal to proximal. The neurovascular bundles were identified first, ligated. Then the dissection was carried down just above the periosteum. Periosteal integrity was ensuring for subsequent graft application. The flap was dissected up to the upper level of lateral malleolus, where the calcaneal artery gets into deeper planes. Then the recipient wound site is prepared and hemostasis is achieved. The flaps were transposed to the defect and inserted with single layer of polypropylene suture. Intermediate thickness split skin grafts (STSG) were harvested from the ipsilateral lateral surface of leg using power dermatome. STSG was meshed manually and secured to the donor defect. Graft stabilized with tie over dressing. Bulky non-compressible dressings were applied, and foot splinted in dorsiflexion. A window was made in the dressing for flap monitoring purposes. First dressing was changed at post op 7 days and graft take were assessed.

### **Results**

There were 4 female patients and 9 male patients. In Table 1 patients age limit is shown. In this study about 40% of them were in between 20-30 years. After the repair of tendo Achilles (50%), if the surgical wound reopens from the flap necrosis, it may cause defects. (Fig. 2). Complication of wounds are shown in Fig. 3. Mostly lesions were visible tendo Achilles without or with visible calcaneus. All the flaps have been survived entirely. They all had good intromission. In Fig. 4. complications are presented. In 1 case epidermal necrosis was developed which was eventually cured with traditional treatment. Much rotation is required in flaps in 30% cases, dog ear deformity aroused. In 1 case, after 14 months, the treatment of dog ear deformity was completed with native anesthesia and in further patients it was improved with time. Vein blocking was not observed however flap edema continued for 3 to 4 days. Apart from 2 (20%) cases, all the cases of skin grafting were done well on the flap donors, fractional losses of graft have been observed which are ultimately cured instinctively by using bandage without secondary graft requirement. In 1 case fractional loss of split-thickness skin graft which rehabilitated instinctively had obtained hypertrophic scar.

**Table 1: Age distribution**

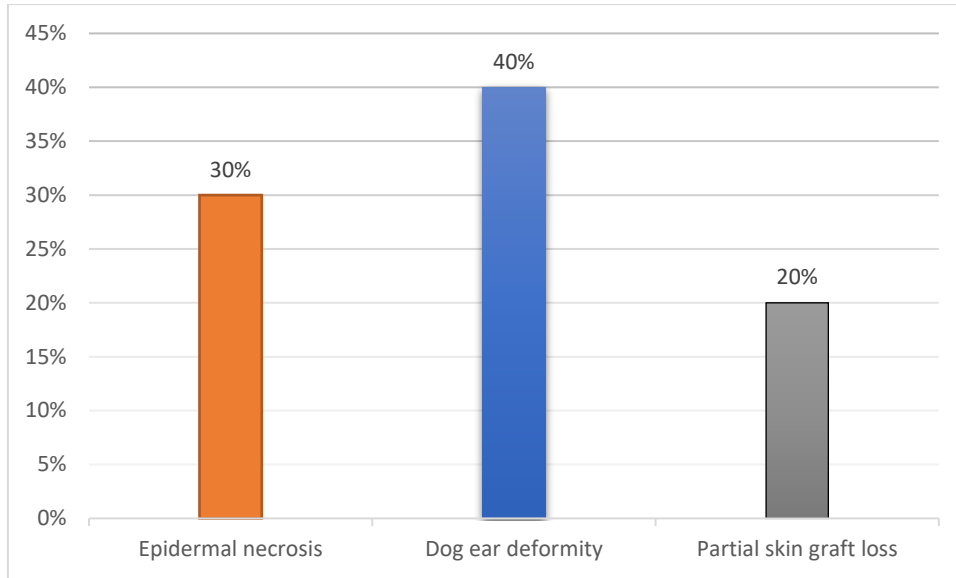
Age range (years)	Number	%
20-30	5	38.48
31-40	3	23.07
41-50	2	15.38
51-60	3	23.07

Table 2 demonstrate etiology, defect area and size, Plaf type and size. Most common etiology in all 13 patients were motorcycle accident followed by crush and so on. The patients mean age was 56.4 years (range=20–60 yrs). The defects size was ranged from 5 × 6 to 15 × 12 cm<sup>2</sup>. The flaps size was

ranged from 5 × 6 to 21 × 9 cm<sup>2</sup>. Patients average follow up period was 8.7 months. The cause of defect was motorcycle accident in two patients, pressure sore in two patients, and single cases were from Achilles tendinitis and tendinous xanthoma. Detailed information presented in Table 2.

**Table 2**

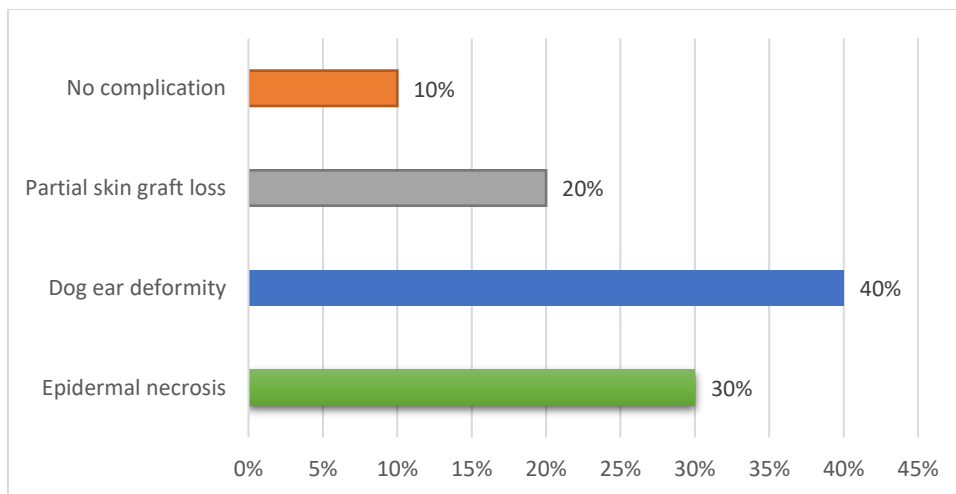
Case	Etiology	Defect area	Defect size	Type of Plaf	Plaf size	Follow up	Results
1	Crush	Achilles area	3x4	Peninsular	3x4	5	Complete healing
2	Crush	Achilles area	5x4	Peninsular	5x4	7	Complete healing
3	Pressure Sore	Achilles area	3x8	Peninsular	3x8	7	Complete healing
4	Pressure Sore	Achilles area	5x15	Peninsular	5x15	9	Complete healing
5	Achilles tendinitis	Achilles area	4x7	Propeller	4x7	11	Complete healing
6	Achilles tendinitis	Achilles area	3x9	Propeller	3x9	15	Complete healing
7	Traffic Accident	Achilles area	5x8	Propeller	5x8	11	Complete healing
8	Tumor Resection	Achilles area	7x6	Propeller	7x6	13	Complete healing
9	Bicycle Accident	Achilles area	8x7	Propeller	8x7	23	Complete healing
10	Motorcycle Accident	Heel pad	6x10	Propeller	6x10	22	Complete healing
11	Tendinous xanthoma	Heel pad	8x11	Propeller	8x11	16	Complete healing
12	Traffic Accident	Heel pad	7x13	Propeller	7x13	27	Complete healing
13	Tumor Resection	Heel pad	4x11	Propeller	4x11	17	Complete healing



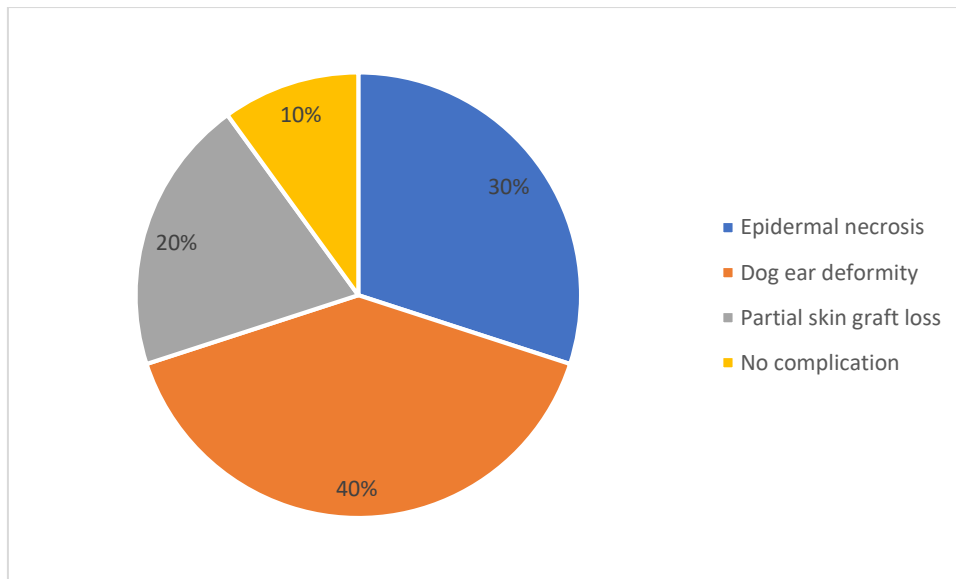
**Figure 2: Distribution of causes of the defects.**

After healing of wound the patients are ambulatory, and movement of ankle wasn't delimited (Fig. 1. D). No succeeding cessation of the grafted skin or of flap is observed by wearing routine shoes. No sensation loss was

observed in the area of flap however at the lateral part of the dorsum of foot sensory disturbance was observed in all cases. All of the flaps were appealingly in a good condition.



**Figure 3: Complexity of the injury.**



**Figure 4: Complications.**

Clinical consequences of flap survival were classified as: a) complete success flap, b) success plus complications, and c) failure of flap. Out of these 13 patients, 10 patients had complete success flap, 2 had success flap success plus complications and 1 failure in flap.

### Discussion

The posterior heel gives an unremitting tough time to the plastic surgeons when the soft-tissue defects reconstructs. Many possibilities to cover the defects of posterior heel are available such as free flap, cross leg flap, local random pattern flap, lateral calcaneal flap, and reverse sural island flap. For the reconstruction of posterior heel, the reverse sural flap (distally based) is finest renowned flap. For treating superior and complex defects, it has larger vascular territory, a broader spectrum of indications and a prodigious rotation arc which combines and make a replacement for the transfer of free tissue. But for posterior heel defects it is not considered a good match as it is insensate, bulkier, generally gives extended linear scars cutting in calf region and across the ankle and skin grafting is required here.<sup>7</sup> Simple methods such as skin grafting can also be suitable in particular conditions but it usually gives undesirable consequences.

As reported, since 1981 the method of lateral calcaneal artery skin flap to reconstruct the defects of heel has been used.<sup>3</sup> Flap used is an fasciocutaneous flap of axial pattern which was sensate, firm and simple. It was promoted by lateral calcaneal artery. Lateral calcaneal

artery is a subdivision of peroneal artery, it is innervated by sural nerve and is exhausted by minor saphenous vein.<sup>4</sup> It is favored in inaccessible posterior heel defects (small sized) or calcaneus without or with visible tendo Achilles.<sup>2</sup> In many circumstances vessels of lower limb are damaged such as in smoking or diabetes mellitus. However peroneal vessels are affected by age, smoking, or in the patients of diabetes mellitus making it innocuous flap.<sup>8</sup> A kinking of the pedicle or a 'dog-ear' possibly will arise because of fasciocutaneous flap which was relocated in form of transposition flap in the area under lateral malleolus. The donor site needs grafting, and this is a drawback of this flap, which gives a depression on the periosteum, and due to this a deprived cosmetic appearance is obtained. Sensory problem in adjacent part of the foot dorsum was also observed by the patients.<sup>9</sup> In the group of 7 patients by Hovius et al, one site of the donor displayed hyperkeratosis which results due to unsuitable planning of the flap and the two sites of donor presents secondary healing.<sup>9</sup> In our group of 13 patients, minimal grafted skin loss was observed in two sites of donor which were cured conventionally with steady dressing.

Many variations of lateral calcaneal flap are present. As reported, in 1996, to cure the small defects on the ankle, lateral calcaneal artery adipofascial flap was used.<sup>10</sup> Advantages of the adipofascial flap includes preservation of sural nerve and the process of donor site skin grafting is not required. Generally, the adipofascial flaps are considered appropriate to reconstruct soft

tissue according to the limits in which thin flap is required, surplus skin around the abrasion is not present, and for visual purposes skin graft is not suitable. Foremost failure of that process is due to raw adipofascial flap surfaces, supplementary skin grafts are used. As in adipofascial flap, skin grafting is not avoided therefore we did not do it in our study.

Cross leg flap is procedure of 2 stages and causes several complications and immobility in the patients. It is moreover immense, insensate and requires a longer hospital stay. For superior defects reconstruction, microsurgical flap is a good preference.<sup>6,11</sup> But it needs high expertise, is immense and cosmetically less suitable.

For posterior heel reconstruction, by many surgeons, lateral calcaneal artery skin flap is preferred as compared to other flap to heal challenging posterior heel wounds on foot. Since there is no sacrifice required for the leg or foot major artery, they are comparatively thin with satisfactory illness at the sites of donor. Moreover, technique of dissection of flap is simple; surgical transfer is easy and vascular pedicle is constant. By using lateral calcaneal flap, drawbacks can be avoided for example, venous congestion, a procedure of 2 stages linked with cross-foot flap, sacrifice of main nerves and arteries, insensate coverage, and requirement for lengthy operation related with sural flap and requirement for refined and skilled personal apparatus related with microsurgical flaps.<sup>9,11</sup> Lateral calcaneal artery flaps have restricted size however they are able to reconstruct posterior heel defects acceptably. All flaps survived well in the current study. In 1(10%) case there was slight epidermal necrosis and in 20% cases only fractional skin graft loss happened that rehabilitated conventionally without requirement of operation. Entire inset areas of flaps are appealingly well excluding areas of donor that exhibited petite depression. No sensation loss has been observed in flap area however in all cases at lateral part of foot dorsum sensory disturbance have been noticed.<sup>9</sup> By this study the effectiveness of lateral calcaneal artery flap in covering of obstinate defects of posterior heel without or with tendon and bone interaction with slight site of donor morbidity has been confirmed.

In current study, thirteen patients' defects presented needing flap were included. Most individuals were from 23 to 45 years. Total of 0 male and 0 female formed study group. Similar reports were revealed from study before,<sup>12</sup>

related to the incidence of age distribution in which they described the most of cases were from 20 to 40 years. In our study most common cause were accident (0 cases, 0%) followed by 0 cases (0%). Another study,<sup>13</sup> revealed that most of defects were caused by road traffic accidents, fall from height, industrial and direct trauma and similar findings were seen in our study.

Current study evaluated the clinical consequence of flap in 03 groups and results were as follows: Lots of cases (83%) had complete flap success, and in 03 patients, outcome was flap success plus complications (14%). 02 patients developed flap failure. Like our results, Lazzeri et al.<sup>14</sup> revealed flap survival rate as 80.7%. another study by Masia et al.<sup>15</sup> revealed 90% survival rate. The rate of success in the present-day studies was very satisfactory with 95% flap take. There were 5% patient cases with total flap loss. Current study establishes the worth of this flap as alternative to free flap. After recovery, patients can resume ordinary life.

## Conclusion

Aim to reconstruct is delivering a sensate and firm coverage to a posterior heel soft tissue defect in addition with slight donor site morbidity. For covering the challenging lesions of the posterior heel in foot, the usage of lateral calcaneal artery skin flap accomplishes entire necessities. It can also be concluded that vigilant selection of optimal and perforator designing of flap result in satisfactory results with use of local perforator flaps for reconstruction. It offers probable clinical upshots with nominal donor site illness, is relatively easy, cost-effective technique and it requires no special micro-surgical instruments or setup.

## References

1. Bajantri B, Bharathi RR, Sabapathy SR. Wound coverage considerations for defects of the lower third of the leg. *Indian J Plast Surg* 2012;45(2):283-90.
2. Suri MP, Patel AG, Vora HJ, Raibagkar SC, Mehta DR, Vyas UH. Post-traumatic posterior heel soft tissue defect reconstruction. *Indian J Plast Surg* 2005;38(2):138-43.

3. Grabb WC, Argenta LC. The lateral calcaneal artery skin flap (the lateral calcaneal artery, lesser saphenous vein, and sural nerve skin flap). *Plast Reconstr Surg* 1981;68(5):723-30.
4. Holmes J, Rayner CR. Lateral calcaneal artery island flaps. *Br J Plast Surg* 1984;37(3):402-5.
5. Ishikawa K, Isshiki N, Hoshino K, Mori C. Distally based lateral calcaneal flap. *Ann Plast Surg* 1990;24(1):10-6.
6. Ishikawa K, Kyutoku S, Takeuchi E. Free lateral calcaneal flap. *Ann Plast Surg* 1993;30(2):167-70.
7. Cheema TA, Saleh ES, De Carvalho AF. The distally based sural artery flap for ankle and foot coverage. *J Foot Ankle Surg* 2007;46(1):40-7.
8. Demirtas Y, Ayhan S, Sariguney Y, et al. Distally based lateral and medial leg adipofascial flaps: need for caution with old, diabetic patients. *Plast Reconstr Surg* 2006;117(1):272-6.
9. Hovius SE, Hofman A, van der Meulen JC. Experiences with the lateral calcaneal artery flap. *Ann Plast Surg* 1988;21(6):532-5.
10. Lin SD, Lai CS, Chiu YT, Lin TM. The lateral calcaneal artery adipofascial flap. *Br J Plast Surg* 1996;49(1):52-7.
11. Chang H, Kwon SS, Minn KW. Lateral calcaneal artery as a recipient pedicle for microsurgical foot reconstruction. *J Plast Reconstr Aesthet Surg* 2010;63(11):1860-4.
12. Mukherjee MK, Alam Parwaz M, Chakravarty B, Langer V. Perforator flap: A novel method for providing skin cover to lower limb defects. *Med J Armed Forces India* 2012;68:328-34. doi: 10.1016/j.mjafi.2012.03.003.
13. Saint-Cyr M, Wong C, Schaverien M, Mojallal A, Rohrich RJ. The perforasome theory: vascular anatomy and clinical implications. *Plast Reconstr Surg* 2009;124:1529-44. doi: 10.1097/PRS.0b013e3181b98a6c
14. Lazzeri D, Huemer GM, Nicoli F, Larcher L, Dashti T, Grassetti L, Li Q, Zhang Y, Spinelli G, Agostini T. Indications, outcomes, and complications of pedicled propeller perforator flaps for upper body defects: a systematic review. *Arch Plast Surg* 2013;40:44-50. doi: 10.5999/aps.2013.40.1.44.
15. Masia J, Moscatiello F, Pons G, Fernandez M, Lopez S, Serret P. Our experience in lower limb reconstruction with perforator flaps. *Ann Plast Surg* 2007;58:507-12. doi: 10.1097/01.sap.0000239841.47088.a5.