

# RIGID BRONCHOSCOPY AND DEBULKING OF AN ENDOBRONCHIAL MYXOMA: AN INCIDENTAL FINDING IN A PATIENT WITH BULLOUS PEMPHIGOID

Jamalul Azizi Abdul Rahaman<sup>1</sup>, Muhammad Asif Khan<sup>2</sup>, Shumaila Javaid<sup>2</sup>, Muhammad Redzwan S. Rashid Ali<sup>3</sup>

## ABSTRACT

Myxoma is a tumor of mesenchymal origin that occurs most frequently in heart. Its endobronchial location is one of its rarest occurrences. They might be asymptomatic in some but can lead to obstructive symptoms in others. Our case pertains to a middle-aged male who presented for his bullous pemphigoid rash. He was later diagnosed with endobronchial Myxoma incidentally. It was managed with less invasive, rigid bronchoscopy followed by Cryo debulking and Argon Plasma Coagulation as compared to surgical resection. This modality reduced the patient's hospital stay, recovery time and ensured curative outcome.

**Keywords:** Rigid Bronchoscopy, Endobronchial Myxoma, Bronchial Tumors

## INTRODUCTION

The term Myxoma was coined by Virchow for a tumor that mimics structure of Wharton Jelly of umbilical cord.(1) Myxoma is one of the most common benign tumor of heart presenting with syncope, fatigue or arrhythmias at any age. (2) While they are frequently encountered in heart, extra cardiac sites of origin include skin, soft tissue, bones, and lungs. Pulmonary Myxoma are exceedingly rare, when they occur, they are found in parenchyma. The tracheobronchial or endo bronchial locations are described in medical literature, in even rarer cases.(3,4) Endo bronchial Myxoma are benign tumors that are known to originate from mesenchymal tissue. Most of the time, they are asymptomatic, but if they grow large enough, they may cause significant airway obstruction, which can lead to a cough, dyspnea, or post-obstructive pneumonia. Due to the non-specific nature of these symptoms, diagnosis is often delayed or can only be incidental. (5)

We present the case of a 58-year-old man who was asymptomatic and was incidentally diagnosed with an endo bronchial Myxoma while he was being treated for bullous pemphigoid. This case shows how a less invasive option like rigid bronchoscopy can help manage endo bronchial Myxoma, as compared to surgical resection, which is a definitive management option.

## CASE PRESENTATION

A 58-year-old non-smoker with no significant occupational exposure presented with symptomatic redness and bullae across his body. He had worked as a warehouse supervisor for years and denied any current or past respiratory symptoms. On examination in addition to his skin bullae, he had left side decreased air entry in upper zone on auscultation. He was diagnosed as bullous pemphigoid and started on a tapering dose of oral steroids.

## INVESTIGATIONS

A baseline chest X-ray was performed and he was referred for opinion from the respiratory physician. The CXR revealed an incidental focal collapse of the left upper lobe (Figure 1a). On further work up a CT thorax was ordered. It revealed Heterogeneous soft tissue mass in left main stem bronchus with collapse of Left upper lobe bronchus (Figure 1b). He was planned for the diagnostic flexible bronchoscopy.

Flexible bronchoscopy revealed a smooth endobronchial mass protruding from the left upper lobe bronchus, causing total obstruction. An endobronchial biopsy was performed, and initial pathological evaluation revealed benign features with myxodegenerative changes,

---

<sup>1</sup> Department of Pulmonology, Thomson Hospital Kota Damansara, Malaysia.

<sup>2</sup> Department of Pulmonology, Hayatabad Medical Complex, Peshawar, Pakistan.

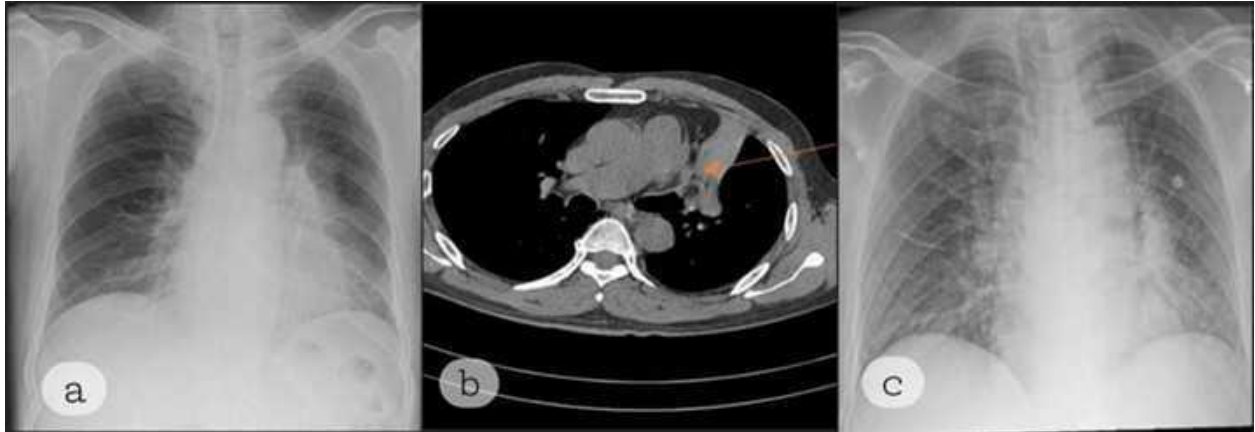
<sup>3</sup> Department of Pulmonology, KPJ Johor Specialist Hospital, Malaysia.

.....  
**Address for Correspondence:**  
**Muhammad Asif Khan**

Assistant Professor  
Department of Pulmonology, Hayatabad Medical Complex Peshawar, Pakistan  
[dr.asifkhaan@gmail.com](mailto:dr.asifkhaan@gmail.com)  
+92 3219029596

hemorrhage, and inflammation. The immune histochemical markers applied for malignancy were negative (CK-7, TTF-1, EMA) so a provisional diagnosis of endobronchial Myxoma was made.

Considering the potential for complete airway obstruction and the benign nature of the lesion, the patient was planned for definitive treatment via rigid bronchoscopy and cryodebulking with electrocautery snare removal.



**Figure 1:**

- a) Chest Xray done at Presentation
- b) CT Thorax slice showing the collapsed bronchus
- c) Chest X-ray done before rigid bronchoscopy and Cryodebulking

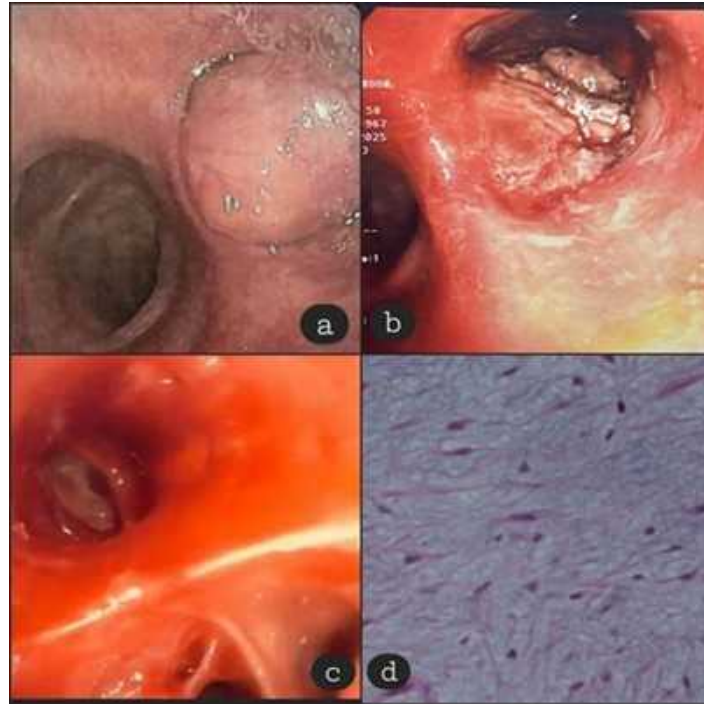#### **TREATMENT**

He was evaluated for general anesthesia assessment and a repeat chest X-ray confirmed the left upper lobe collapse (Figure 1c). Following all the protocol for rigid bronchoscopy, procedure was initiated. Intraoperatively, rigid bronchoscopy showed a smooth, lobulated mass completely obstructing the ostium of the left upper lobe (Figure 2a). The initial attempt to snare the lesion with an electrocautery snare was difficult as the base and stalk could not be adequately grasped. Multiple rounds of cryodebulking were performed using both a 1.7 mm and 2.4 mm cryoprobe to de bulk the tumor. Following this, a second attempt with the snare was successful, and the mass was removed in its entirety, revealing a raw base (Figure 2b). A small residue at the base was treated with argon plasma coagulation (APC) to prevent recurrence and stop minimal bleeding.

Hemostasis was secured with cold saline, 1 in 20000 adrenaline and 1 gm tranexemic acid flushes. After the procedure, the patency of the left upper lobe was re-established, and mucus plugs were suctioned out (Figure 2c). Postoperatively, the patient had minimal bronchospasm but recovered well. He was given prophylactic antibiotics and nebulized bronchodilators, and his steroid treatment for bullous pemphigoid was continued.

#### **OUTCOME AND FOLLOWUP**

He was discharged after two days in good condition. The final histology report confirmed a low-grade spindle cell lesion with myxoid stroma and an adipose component (Figure 2d). The patient was discharged after 2 days stay at hospital and was sent home on oral antibiotics. Currently, the patient is asymptomatic and is due for regular follow-up and bronchoscopy surveillance.



**Figure 2:**

- a) Pre Debulking**
- b) Post Debulking**
- c) Post Debulking distal to Myxoma**
- d) Histology of Endobronchial Myxoma**

## **DISCUSSION**

This case highlights a rare condition, an endobronchial Myxoma discovered incidentally. His skin disease provided an opportunity for the workup and management of his underlying and undiscovered respiratory condition. Mostly, these are managed surgically but use of rigid bronchoscopy with cryodebulking and electrocautery proved an effective modality in reestablishing the airway patency. Literature reports very few cases of endobronchial myxoma corresponding to the rarity of its occurrence and they were primarily managed with surgical excision. Rigid bronchoscopy with APC coupled with close follow up was reported to be an alternative. (6)

Tumor debulking strategies with a bronchoscope are used commonly in treating critical airway obstructions: (7,8) The traditional way of managing airway tumors is usually surgical resection in the form of lobectomy or pneumonectomy. It has been considered as the standard of care for these lesions offering a definitive curative approach. However, it carries high degree of morbidity, including anesthesia complications, risk of infection, prolonged recovery and permanent loss of tissue. The

successful management of this case, contrary to the traditional surgical resection has highlighted a less invasive mode of management in selected patients as an effective alternative

The combination of cryodebulking and electrocautery snare removal completely excises the tumor while preserving the surrounding lung parenchyma. The use of argon plasma coagulation (APC) on the tumor's base helped in minimizing the risk of local recurrence. (9) This modality reduced the patient's hospital stay, recovery time and ensured curative outcome.

## **LEARNING POINTS**

This case report emphasizes the importance of thorough diagnostic evaluation, even in patients with an unrelated and seemingly complete diagnosis. The successful use of rigid bronchoscopy with electrocautery and cryodebulking for a symptomatic endobronchial Myxoma led to a complete and curative outcome for the patient.

## **DECLARATIONS**

Author has no declaration to make.

**Patients consent for use of data for publication:**

This data is being published with the written informed consent of the patient.

**Conflicts of Interests:**

Author has no conflict of interest

**Funding:**

Author has no funding to declare.

**Acknowledgements:**

Case presented, worked up and managed at KPJ Johor Specialist Hospital, Johor Bahru, Malaysia.

**REFERENCES**

1. Matsuoka H, Takata Y, Maeda S. Primary Pulmonary Myxoma. *Ann Thorac Surg.* 2005 Jan;79(1):329–30. doi:10.1016/j.athoracsur.2003.08.011
2. McCoskey EH, Mehta JB, Krishnan K, Roy TM. Right Atrial Myxoma With Extracardiac Manifestations. *Chest.* 2000 Aug;118(2):547–9. doi:10.1378/chest.118.2.547
3. Kim GH, Lim CS, Ahn HS, Choi SI, Lee HB, Lee YC, et al. A Case Report of Myxoma in the Lung. *Tuberc Respir Dis.* 1997;44(5):1172–6.
4. R R, R P, R E, L F, R N, J C. Endobronchial myxoma--case report. *Rev Port Pneumol.* 2012 Jun;18(3). doi:10.1016/j.rppneu.2011.12.004 PubMed PMID: 22261261.
5. Pulmonary microcystic fibromyxoma: Report of 3 cases - PubMed [Internet]. [cited 2026 Mar 18]. Available from: <https://pubmed.ncbi.nlm.nih.gov/17063085/>
6. Uluşan A, Tunca İE, Şanlı M, Işık AF. Endobronchial lesions cases treated with interventional bronchoscopic techniques: Our single-center experiences. *Turk J Thorac Cardiovasc Surg.* 2020 Apr 22;28(2):352–8. doi:10.5606/tgkdc.dergisi.2020.18708 PubMed PMID: 32551167; PubMed Central PMCID: PMC7298361.
7. Mahmood K, Wahidi MM. Ablative therapies for central airway obstruction. *Semin Respir Crit Care Med.* 2014 Dec;35(6):681–92. doi:10.1055/s-0034-1395501 PubMed PMID: 25463159.
8. Migrating tumor: A serious complication of use of endobronchial snare loop - Rowan University [Internet]. [cited 2026 Mar 18]. Available from: <https://www.researchwithrowan.com/en/publications/migrating-tumor-a-serious-complication-of-use-of-endobronchial-sn/>
9. Shepherd RW, Radchenko C. Bronchoscopic ablation techniques in the management of lung cancer. *Ann Transl Med.* 2019 Aug;7(15):362. doi:10.21037/atm.2019.04.47 PubMed PMID: 31516908; PubMed Central PMCID: PMC6712260.