

ORGANOPHOSPHORUS INDUCED DELAYED NEUROPATHY (OPIDN); TYPE III PARALYSIS PRESENTING 3 WEEKS AFTER THE INITIAL ORGANOPHOSPHORUS EXPOSURE

Hafez Mohammad Ammar Abdullah¹, Muhammad Asim Shahzad², Waqas Ullah¹, Faiz Saeed¹, Uzma Ikhtiar Khan³, Sumbal Aziz³

SUMMARY

Organophosphates are carbon and phosphate containing compounds that are potent inhibitors of the enzyme acetylcholinesterase which normally degrades acetylcholine. This results in an excess of acetylcholine which can trigger cholinergic toxicity. Organophosphate poisoning can be classified into 3 types based primarily on their symptoms and timeline of their appearance. Type I paralysis or cholinergic syndrome which occurs within hours is due to the excessive stimulation of nicotinic receptors by acetylcholine. Type II paralysis or intermediate syndrome usually appears 24 to 96 hours after poisoning. The clinical features are muscular weakness affecting predominantly the proximal muscles and neck flexors. The weakness starts from ocular muscles and spread towards the muscles of head and neck and then the proximal limb and respiratory muscles. Type III paralysis or organophosphate induced delayed neuropathy (OPIDN) is a pure motor or predominantly motor axonal neuropathy characterized by flaccid limb paralysis with minimal or no sensory loss, which occurs 2-3 weeks after exposure to an organophosphate agent. Here we are presenting the case of a 30 years old female who presented with progressive lower and then upper limb weakness and paresthesias, 3 weeks after her initial exposure to organophosphate compounds.

CASE PRESENTATION

A 35 years old married lady with 4 female off springs, hailing from Afghanistan, presented with the chief complaints of progressive bilateral lower limb weakness for the last 20 days, paresthesias involving bilateral lower limb for the last 20 days, and now progressing to the fingers. She also had weakness of the right sided fingers particularly on the lateral aspect to the extent that the patient had trouble holding a spoon. She also complained of pain in the cervical region of the spine.

There was no history of urinary or faecal incon-

¹ Dept of Internal Medicine, Khyber Teaching Hospital

² Dept of Internal Medicine, Hayatabad Medical Complex

³ Independent research scholar

Address for Correspondence:

Dr. Muhammad Asim Shahzad

Department of Medicine, Hayatabad Medical Complex, Peshawar - Pakistan.

E-mail: asim_shehzad786@yahoo.com

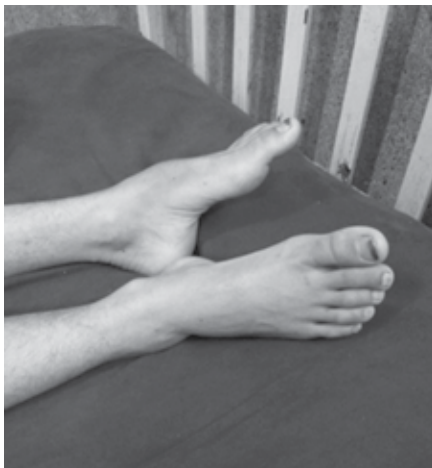
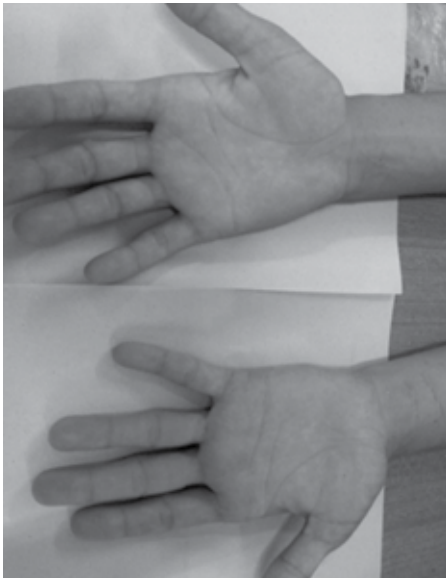
tinence, no dizzy spells on standing, palpitations or flushing. There was no previous history of surgical procedures, no family history of neurological diseases. The patient was on no long term medication. The patient was asked in detail about her past history and she gave a history of exposure to insecticides 20 days back. She developed clinical features consistent with organophosphate poisoning and was treated at a local hospital. The patient had made a complete recovery within 24 hours. On further probing the patient also gave a history of domestic violence with trauma to the head and the cervical spine.

GENERAL PHYSICAL EXAMINATION

On general physical exam, the patient was vitally stable and fully oriented in time, place and person. Her pulse was regular and there was no postural hypotension. Her remaining GPE was completely normal.

Her CNS examination showed intact cranial nerves (fig-1 Facial Nerve Testing) and no signs of meningism. Her upper limbs showed wasting of the thenar and hypothenar eminences with guttering on the dorsal aspect of inter digital spaces more on the right side. There was a decreased sensation in the median nerve territory bilaterally though Tinel sign, Oschner sign and the reverse prayer sign were all negative. Power was decreased in right hand fingers.





Her lower limb examination showed bilateral foot drop with a power of 0/5 at the ankle and the metatarsophalangeal joints bilaterally. The power was 5/5 for the rest of the lower limb bilaterally. There was also bilateral hyporeflexia at the ankle joints. Plantars were bilaterally equivocal.

Sensory examination showed decreased sensation of all modalities bilaterally below the knee (L3). A digital rectal exam performed showed no sensory deficit and a normal anal tone.

The Musculoskeletal system showed no limitation of neck movements. The spine was normal on inspection and palpation. The rest of the systemic exam was completely unremarkable.

DIFFERENTIALS

At this stage the following differentials were considered;

Compressive cervical myelopathy

Guillain barre syndrome

Organophosphorus induced delayed paralysis

Vitamin B12 deficiency

Tabes dorsalis

Diabetic neuropathy

HIV neuropathy

Hypothyroidism

Multiple Sclerosis

Malignancy like Lymphoma

INVESTIGATIONS

The patient was thoroughly investigated. Her labs showed an Hb of 11.0 g/dl with normal indices (MCV=84), a TLC of 5,900 cells/mcL, a PLT count of 182,000/mcL. Her ESR was 15mm/1st hour. Her serum LDH was 522 mg/dl (150-450) serum Calcium was 9.9 mg/dl, her RBS was 78 mg/dl. Serum urea and creatinine were 54 mg/dl and 0.86 mg/dl. Her SGPT was 38 IU/dl, Serum electrolytes were normal. Her serology for HBV, HCV and HIV was also negative. ANF VDRL and TPHA negative. Her TSH was 1.63 IU/dl (Normal).

The patient's chest X ray, abdominal sonography and EKG were also normal. MRI of the brain and spinal cord were completely normal too. Her CSF was studied which also came out to be normal. This was followed by nerve conduction studies. The Nerve conduction studies showed acute denervation of the upper and lower limb muscles, including the right median, ulnar, tibial and common peroneal motor nerves and on the left side, the common peroneal and tibial nerves, possibly Acute Motor Axonal Neuropathy.

DISCUSSION

Organophosphates are esters of phosphoric acid, mainly used as insecticides and about 53 different preparations are available worldwide. Organophosphates (OPs) are broadly divided into nerve agents and insecticides. An estimated 3,000,000 people are exposed to organophosphate or carbamate agents each year, with up to 300,000 fatalities.^{1,2} They can enter the body through the skin, by inhalation and ingestion though cases of OP toxicity by ingestion of contaminated fruit, flour, or cooking oil, and wearing contaminated clothing are also common. They are also found in some popular household roach and ant sprays. Several OP nerve agents were also developed in Germany during the 2nd world war, but with the exception of the 1995 Tokyo subway attacks, they have never been actually used.

The presentation of OP poisoning is usually acute with signs and symptoms of cholinergic toxicity developing within hours. However 3 different patterns of acute OP poisoning are recognized, based on their presentation and time from exposure, they include;

Type I paralysis or cholinergic syndrome: It occurs within hours due to excessive stimulation of nicotinic receptors by Ach due to blockade of acetylcholinesterase (AChE) by an OP agent. However poisoning through the skin may take up to 24 hours. Other features of the acute presentation include central and autonomic nervous systems.

Type II paralysis or intermediate syndrome: It is a distinct clinical entity having incidence of 8-50% and it usually appears 24 to 96 hours after poisoning. The cardinal clinical features comprise muscular weakness affecting predominantly the proximal muscles and neck flexors. The weakness starts from ocular muscles and spread towards muscles of head and neck, then the proximal limb muscles and the respiratory muscles. Risk factors for the development of intermediate syndrome appear to include exposure to a highly fat-soluble organophosphorus agent.³ Recovery is rule in 5-18 days unless infections, respiratory failure or cardiac arrhythmias complicate the course.^{4,5} Nerve conduction studies on patients with intermediate syndrome reveal unique postsynaptic abnormalities that differentiate this disorder from delayed neurotoxicity.⁶

Type III paralysis or organophosphate induced delayed neuropathy (OPIDN) is a pure motor or predominantly motor axonal neuropathy characterized by wrist drop and foot drop with minimal or no sensory loss which occurs 2-3 weeks after exposure to an OP agent. The pathogenesis of OPIDN is different than the other 2 types of paralysis. It is presumed to be due to phosphorylation and ageing of an enzyme in the axons called neurotoxic esterase or neuropathic target esterase (NTE). Inhibition of NTE causes degeneration of predominantly long axons, with loss of myelin and

macrophage accumulation in nerves leading to motor axonal neuropathy.^{7,8} Sensory disturbances are usually mild. Delayed neurotoxicity primarily affects distal muscle groups, but in severe neurotoxicity, proximal muscles groups may also be affected.⁹ Electromyograms and nerve conduction studies of affected patients reveal decreased firing of motor conduction units.¹⁰ Histopathologic sections of peripheral nerves reveal Wallerian (or "dying-back") degeneration of large distal axons.¹¹

Chronic organophosphate induced neuropsychiatric disorder (COPIND): Residual deficits from acute OP poisoning can lead to confusion, lethargy, Anxiety, emotional lability, depression, psychosis, aggression, hallucinations, problems with memory and concentration, dystonic reactions, schizophrenia, cog-wheel rigidity and choreoathetosis.^{12,13,14}

A striking example of OPIDN occurred during the 1930s, when an OP derivative contaminated whisky caused a neurological syndrome Ginger Jake Paralysis that crippled as many as 50,000 persons. The drink "Ginger Jake," contained tri-ortho-cresyl phosphate (TOCP) which resulted in partially reversible neurologic damage. The damage resulted in the limping "Jake Leg" or "Jake Walk".¹²

Another case report was published in JAPI vol 55 2007, about a 19 years old young male who after attempted suicide developed within 20 days, high stepping gait, distal motor deficit in lower limbs (O/5) and atrophy of distal group of muscles. Biceps, supinator and triceps reflexes were absent in both upper limbs. Plantars were bilaterally silent. NCS showed AMAN and a mild sensory neuropathy affecting median and ulnar nerves bilaterally.

In 1942 a strange epidemic paralysis started in Saval. The epidemic went on for several months and affected 41 people, all working as owners or labourers on the same farm. Most of the cases presented as spastic paraplegia and lower leg muscle atrophy without sensory impairment and was diagnosed as OPIDN only after 50 years!¹⁵

MANAGEMENT

There is still no consensus on the management of OPIDN. Some prefer physiotherapy alone, but it may take up to 9 months to recover.¹⁶ The hyperaesthesias may be controlled by amitriptyline, carbamazepine and capsaicin. The use of thiamin is recommended by some authors but it has not been shown to alter the appearance of OPIDN.¹⁷ It is also suggested that recovery or good prognosis will be expected with B1, B2, B6, B12 and methylprednisolone as long as they are given before paralysis develops in delayed neuropathy.¹⁸

However a paucity of cases and lack of large scale follow up studies means that there is not going to be a consensus management plan anytime soon.

FOLLOW UP

The patient was followed up 1 month after her discharge. The power at the ankle joint increased from 0/5 to 2/5. The plantars were still equivocal. The parathesias had considerably improved. The limb weakness also improved significantly. The patient was undergoing regular physiotherapy at home with once a month reassessment of the technique.

REFERENCES

1. Eddleston M, Phillips MR. Self-poisoning with pesticides. *BMJ* 2004; 328:42.
2. Eyer P. The role of oximes in the management of organophosphorus pesticide poisoning. *Toxicol Rev* 2003; 22:165.
3. Groszek B, Pach J, Kłys M. Intermediate syndrome in acute fenitrothion poisoning. *Przegl Lek* 1995; 52:271.
4. Samuel J, Thomas K, Jesaseelan L, et al. Incidence of intermediate syndrome in organophosphorus poisoning. *J Assoc Phys India* 1995; 43:321-3.
5. Wadia RS, Shinde SN, Vaidya S. Delayed neurotoxicity after an episode of poisoning with dichlorovos. *Neurology India* 1985; 33:247-53.
6. De Bleecker J, Van den Neucker K, Colardyn F. Intermediate syndrome in organophosphorus poisoning: a prospective study. *Crit Care Med* 1993; 21:1706.
7. Morgan (1978); Segalla, Spencer (2011), "The 1959 Moroccan Oil Poisoning and US Cold War Disaster Diplomacy," *Journal of North African Studies*.
8. Chatterjee M, Sharma PS. Unusual neurological complications in a case of organophosphate poisoning. *Neurol India* 2003; 51:290-
9. Abou-Donia MB. Organophosphorus ester-induced chronic neurotoxicity. *Arch Environ Health* 2003; 58:484.
10. Aygun D, Onar MK, Altintop BL. The clinical and electrophysiological features of a delayed polyneuropathy developing subsequently after acute organophosphate poisoning and its correlation with the serum acetylcholinesterase. *Electromyogr Clin Neurophysiol* 2003; 43:421.
11. Johnson MK. Organophosphorus esters causing delayed neurotoxic effects: mechanism of action and structure activity studies. *Arch Toxicol* 1975; 34:259.
12. Lall SB, Peshin SS, Seth SD. Acute poisoning : a ten years retrospective study. *Ann Natl Acad Med Sci(India)* 1994; 30 : 35-44.
13. Jayaratnam J : Pesticide poisoning as a global health problem. *World Health Stat Q* 1990; 43 : 139-144.
14. Karalliedde L. Organophosphorus poisoning and anaesthesia. *Anaesthesia* 1999; 54 : 1073-1088
15. Tosi L, Righetti C, Adami L, et al. A strange epidemic paralysis in Saval, Verona, Italy. Revision and diagnosis 50 years later of tri-ortho-cresyl phosphate poisoning. *J Neurol Neurosurg Psychiatry* 1994 Jul; 57(7):810-3.
16. Senanayake N. Tri-cresyl phosphate neuropathy in Sri Lanka: a clinical and neurophysiological study with a three year follow up. *J Neurol Neurosurg Psychiatry* 1981; 44:775-780.
17. Agapejev S, Vassiliev I, Lima MMF. Neurologic manifestations in 93 patients with exogenous intoxication by non-medicamentous chemical substances. *Arq Neuropsiquiatr* 1986; 44:232-242.
18. Fengyuan Piao, Ning Ma, Hidetaka Yamamoto, et al. Effects of Prednisolone and Complex of Vitamin B₁, B₆, B₁₂ and B₁₅ on Organophosphorus Compound-Induced Delayed Neurotoxicity.

ONLINE SUBMISSION OF MANUSCRIPT

It is mandatory to submit the manuscripts at the following website of KJMS. It is quick, convenient, cheap, requirement of HEC and Paperless.

Website: **www.kjms.com.pk**

The intending writers are expected to first register themselves on the website and follow the instructions on the website. Author agreement can be easily downloaded from our website. A duly signed author agreement must accompany initial submission of the manuscript.